Why the ‘eyes are the liars’

Relevance of the AVNS in Patient Care and Management in whiplash & mTBI Patients

Brenda E. Berge, Au.D. , F-ADA
Doctor of Audiology, Fellow ADA

*Important Note**

- Images in this presentation are used with permission from the sources or as set out in the rules of use
- They are not to be reproduced without permission or used for distribution
- Referencing and acknowledgment of these copyrights are provided

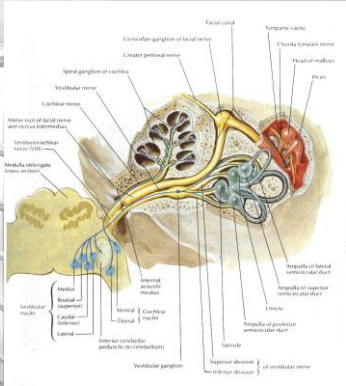

Vestibulocochlear Nerve: Schema

Membranous Labyrinths

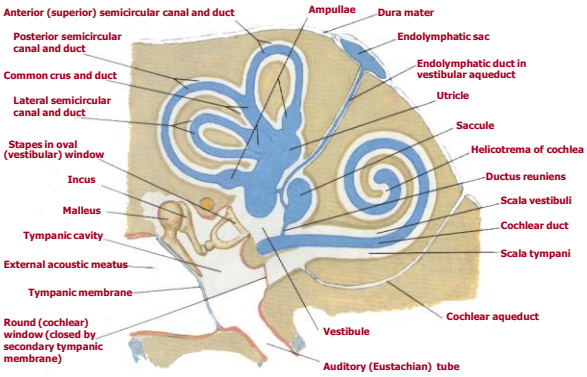

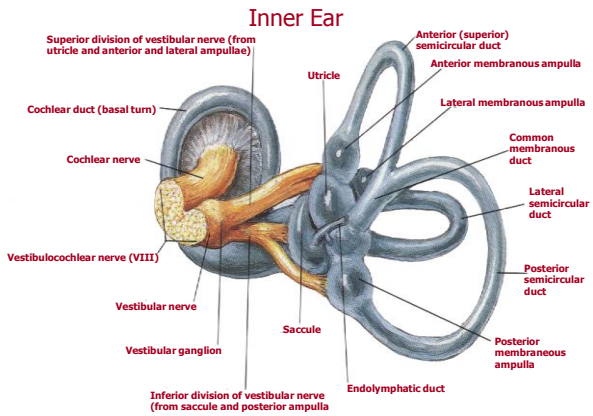
Inner Ear
Superior division of vestibular nerve (from utricle and anterior and lateral ampullae)
Anterior (superior) semicircular duct
Anterior membranous ampulla
Utricle
Cochlear duct (basal turn)
Lateral membranous ampulla
Common membranous duct
Cochlear nerve
Lateral semicircular duct
Vestibulocochlear nerve (VIII)
Posterior semicircular duct
Vestibular nerve
Saccule
Vestibular ganglion
Posterior membraneous ampulla
Endolymphatic duct
Inferior division of vestibular nerve (from saccule and posterior ampulla

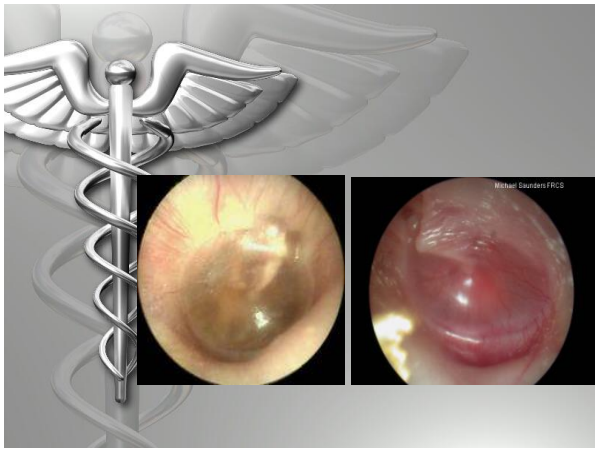
Michael Saunders FRCS

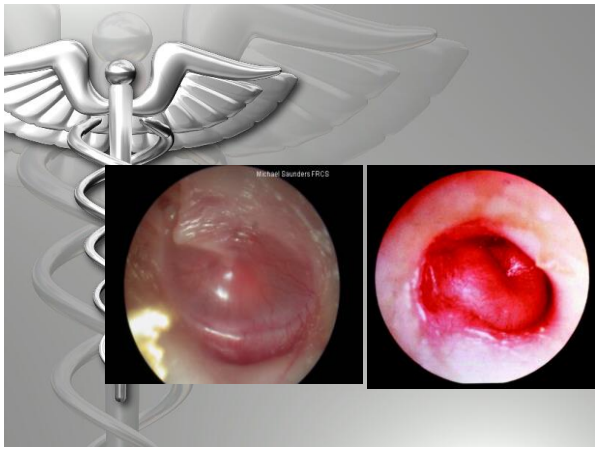
Michael Saunders FRCS

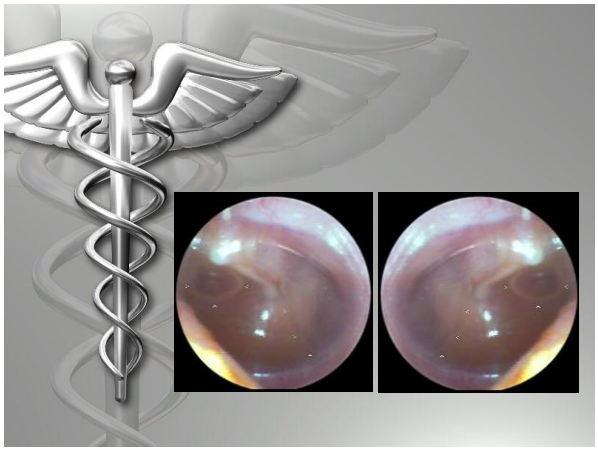

Axial T2 MRI

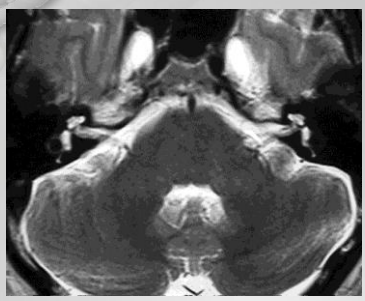

http://www.emedicine.com/ent/images/Large/597REVD622Ccloseupnorm_2.jpg

Cochlea

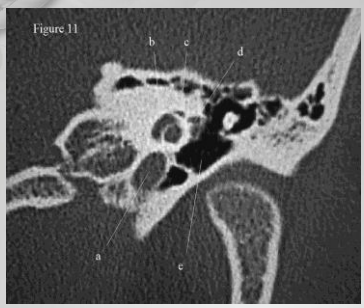

http://www.emedicine.com/ent/images/Large/664698FIG11.JPG

Superior Canal Dehiscence

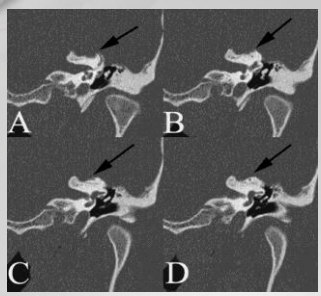

http://www.emedicine.com/ent/images/Large/21472147SCDS.jpg

Digital cadaver images from the VHP data sets proved to be just the tool that these authors needed to support their finding of a muscle-dura connection; they were able to view the connection in full-color computerized cross-sections. Future research plans include using the VHP data sets to construct 3-D models of the connection that will enable simulations of its movement and determination of its roles in function and dysfunction.

New piece in the headache puzzle?

What is the clinical significance of this new discovery? The investigators postulate that the normal function of the newfound connection may be to resist the inward folding of the dura, which tends to occur when the neck is extended or the head tipped backward.

The University of Maryland scientists who discovered one, then apparently a second, muscle-dura connection were able to verify their findings by using computer-generated digital cadaver images from the amazing Visible Human Project. The circles indicate the region of the two previously unappreciated tissue bridges.

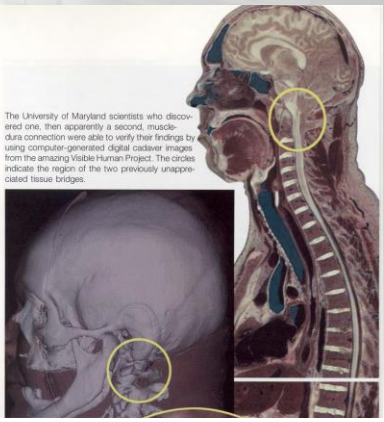

Auriculotemporal Nerve

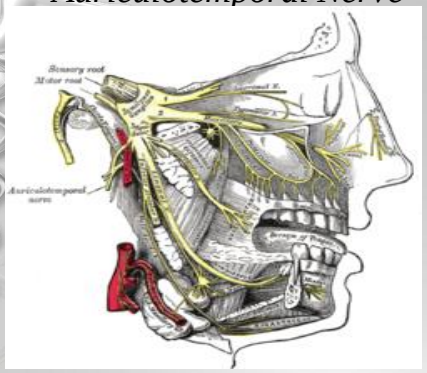

Courtesy of Gary D. Hack, Gwendolyn Dunn, and Mi Young Toh

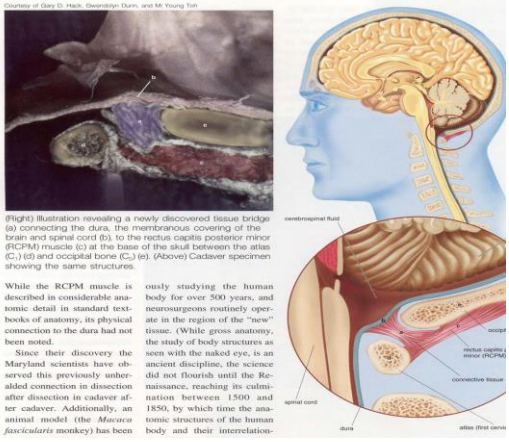

(Right) Illustration revealing a newly discovered tissue bridge (a) connecting the dura, the membranous covering of the brain and spinal cord (b), to the rectus capitis posterior minor (RCPM) muscle (c) at the base of the skull between the atlas (C_1) (d) and occipital bone (C_0) (e). (Above) Cadaver specimen showing the same structures.

While the RCPM muscle is described in considerable anatomic detail in standard textbooks of anatomy, its physical connection to the dura had not been noted.

Since their discovery the Maryland scientists have observed this previously unheralded connection in dissection after dissection in cadaver after cadaver. Additionally, an animal model (the *Macaca fascicularis* monkey) has been ously studying the human body for over 500 years, and neurosurgeons routinely operate in the region of the "new" tissue. (While gross anatomy, the study of body structures as seen with the naked eye, is an ancient discipline, the science did not flourish until the Renaissance, reaching its culmination between 1500 and 1850, by which time the anatomic structures of the human body and their interrelation-

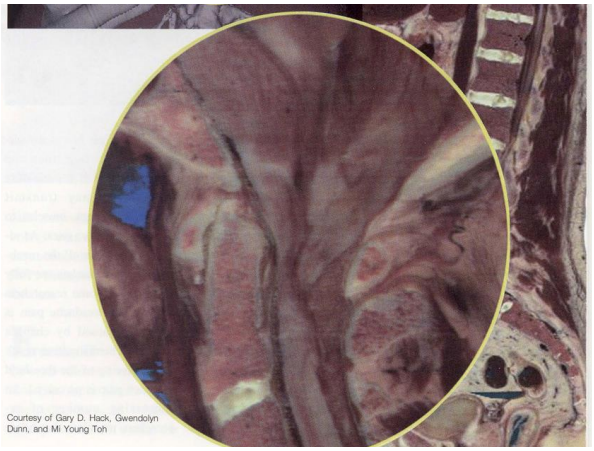

Courtesy of Gary D. Hack, Gwendolyn Dunn, and Mi Young Toh

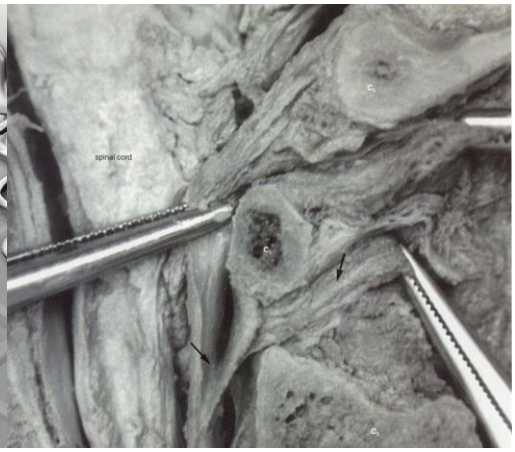

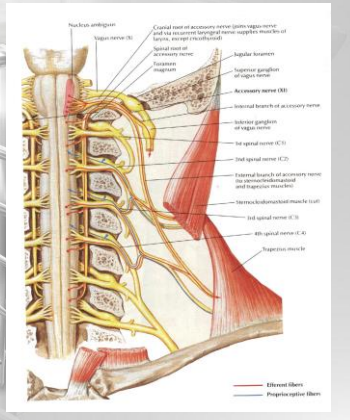

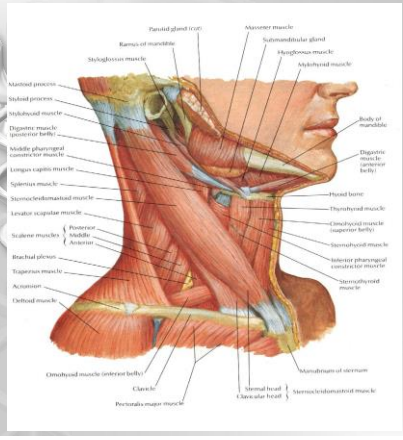

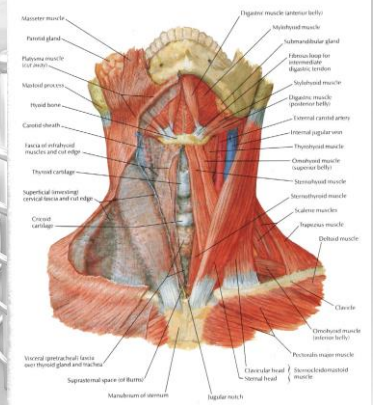

Muscles of Neck: Anterior View

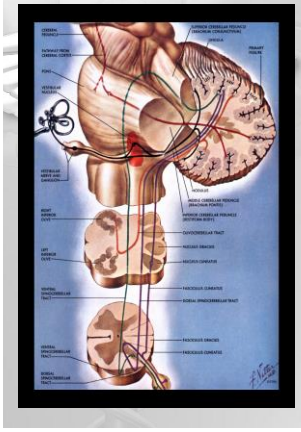

VSR

VESTIBULO-SPINAL REFLEX

SENDS DESCENDING MOTOR CONTROL SIGNALS TO THE MUSCULOSKETAL SYSTEM FOR POSTURAL CONTROL

VCR

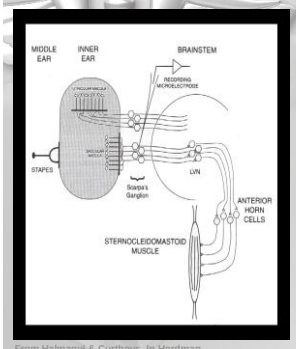

From Halmagyi & Curthoys, In Herdman

VESTIBULOCOLLIC REFLEX

ACTS ON THE MUSCLES IN THE NECK TO STABLIZE THE HEAD. THE HEAD RESPONDS TO MOVEMENT SENSED BY THE OTOLITHIC OR SCC ORGANS.

Cervical Reflexes

COR - Cervico-Ocular: Eye movements driven by the neck muscle proprioceptors. COR supplements the VOR.

CSR - Cervicospinal: Changes in limb position driven by neck muscle afferent activity. CSR supplements the VSR.

CCR - Cervicocollic: Cervical reflex that stabilizes the head on the body.

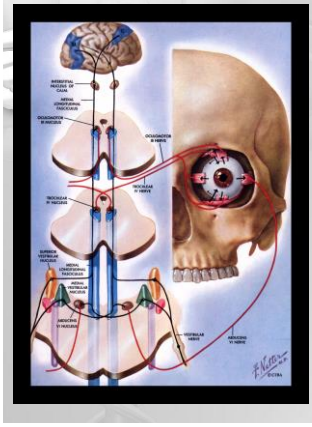

VOR

VESTIBULOCULAR REFLEX

ALLOWS VISUAL STABILIZATION DURING ACTIVE HEAD MOVEMENT

Peripheral pathways for vertigo and nystagmus

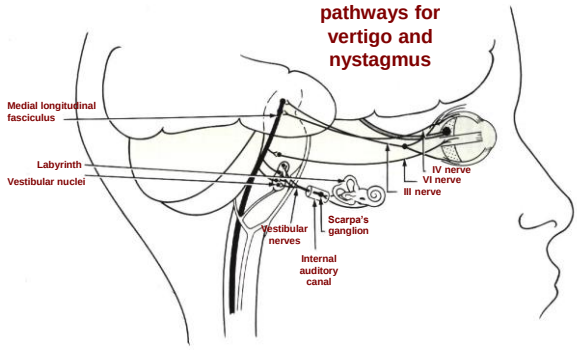

Modified Fully-Supported Hallpike - BPPV



Vertebral Artery Test



VOG Screening- Congenital Nystagmus